

Dose Related Histological Changes in Mouse Kidney After Administration of Manuka Honey

Sidrah Saleem,¹ Nadia Naseem,² Abdul Hannan,¹ Abdul Hannan Nagi,² Muhammad Usman Qamar¹ and Naeem Akhtar³

¹Microbiology Department, University of Health Sciences, Lahore

²Morbid Anatomy and Histopathology Department, University of Health Sciences Lahore

³Department of Microbiology, Shaikh Medical Complex, Rahim Yar Khan

Abstract.- Honey has been used for both nutritional purposes as well as medicinal purposes. The present study describes dose related histological effects of Manuka honey on mouse kidney. Another important purpose is to evaluate the dose tolerance of this natural product for its future exploitation as a therapeutic agent. Forty eight BALB/c mice were divided into six groups each of eight mice. Manuka honey was given orally at a dose of 5, 10, 15, 25 and 35 mL/kg body weight to five groups for two weeks, whereas the sixth was kept as the control group. All the animals were sacrificed on day 15, their kidneys were dissected out and processed for histological analysis. No animal mortality occurred at any of the honey doses. Focal tubular epithelial degeneration, tubular epithelial coagulative necrosis, interstitial inflammation of chronic type comprising lymphocytes and plasma cells and glomerulus mesangial proliferation was observed in a dose dependent manner. Manuka honey given orally in different doses was well tolerated by the experimental mice and no abnormal clinical signs and symptoms were recorded. The higher doses, however, brought some significant histological changes in mice kidney.

Key words: Manuka honey, dose tolerance, BALB/c, kidney histology.

INTRODUCTION

Honey has been used for the treatment of many ailments since ancient times (Olaitan *et al.*, 2007). It is produced from many floral sources and its therapeutic efficacy varies with its origin and processing (Irish *et al.*, 2011). It has been found to be effective against bacteria, fungi and parasites (Mullai and Memon, 2007; Maeda *et al.*, 2008). In addition its role in promoting the healing process, decreasing inflammation and stimulating tissue regeneration (Medhi *et al.*, 2008; Jalali *et al.*, 2007; Schencke *et al.*, 2011) has been documented many times (Yusofa *et al.*, 2007; Sukur *et al.*, 2011). Honey contains more than 100 components in it which are responsible for its multi-dimensional performance (Simon, 2009; Hannan, 2009). Although there are lot more studies that narrate the therapeutic and biological properties of this natural product, information regarding the dose tolerance and safety of honey is not much reported in the literature.

The aim of the present study was to evaluate dose tolerance of Manuka honey as well as the histological changes induced by it in the mouse kidney.

MATERIALS AND METHODS

This experimental study was conducted in the Department of Microbiology and Experimental Research Laboratory, University of Health Sciences, Lahore. The study was approved by the ethical committee of the university.

Honey

Manuka honey was obtained from Comvita, New Zealand and was stored in refrigerator at 3-4°C in its dark coloured bottle.

Animals

BALB/c mice, 12-14 weeks of age, weighing 25-30 g were obtained from University of Health Sciences, Lahore. They were divided into 6 groups each of eight mice and were given honey as 5, 10, 15, 25 and 35mL/kg body weight to five groups. One group was kept as control and was not given honey. The animals were housed group wise in separate cages duly labelled and having clean

* Corresponding author. sidu_78@yahoo.com
0030-9923/2015/0001-0235 \$ 8.00/0
Copyright 2015 Zoological Society of Pakistan

compact husk made beds with the room temperature maintained at 20-25°C They were fed with the standard animal feed and water *ad libitum* and a 12 h day and 12 h night cycle was adopted (Munira *et al.*, 2010).

Procedure adopt

All the mice were kept deprived of water 3 h before honey dose. Diluted honey (70% v/v) was given orally with the help of a feeding syringe. Mice were given honey in divided doses (BID) for 14 consecutive days. Several observations like mouse alertness, urine colour, stool consistency etc. were also made during and after feeding. On day 15 the animals were sacrificed by deep anaesthesia using chloroform (Sigma-Aldrich USA) (AVMA, 2001). Kidneys were dissected out carefully and were fixed in 10% formal saline. After overnight fixation appropriate tissue sections about 4-6 μ m were cut from the representative areas of the specimen. These sections were processed through different gradations of alcohol and embedded in wax (Bancroft, 2008). From each tissue block, 4-6 μ m thick sections were cut and then stained in haematoxylin and eosin.

Statistical analysis

Data was entered and analyzed using SPSS, version 17.0. Percentages are given for qualitative variables. P-value shows association in between honey dose groups and histological changes induced. A p-value < 0.05 is considered to be significant when Pearson Chi-square test applied.

RESULTS

No animal mortality occurred at any honey dose. Focal tubular epithelial degeneration (Fig. 1B, arrow 2) was seen in 1 (12%), 8 (100%), 4 (50%) and 8 (100%) animals of 10, 15, 25 and 35 mL/kg body weight groups, respectively (Fig. 2A). Tubular epithelial coagulative necrosis was seen only in 1 (12%) (Fig. 2B) animal of group 25 mL/kg (p-value 0.403). The rest did not demonstrate any necrotic changes. Interstitial inflammation (Fig. 1B, arrow 4, and Fig. 1C) of chronic type comprising lymphocytes and plasma cells was observed in all the experimental mice other than the control group.

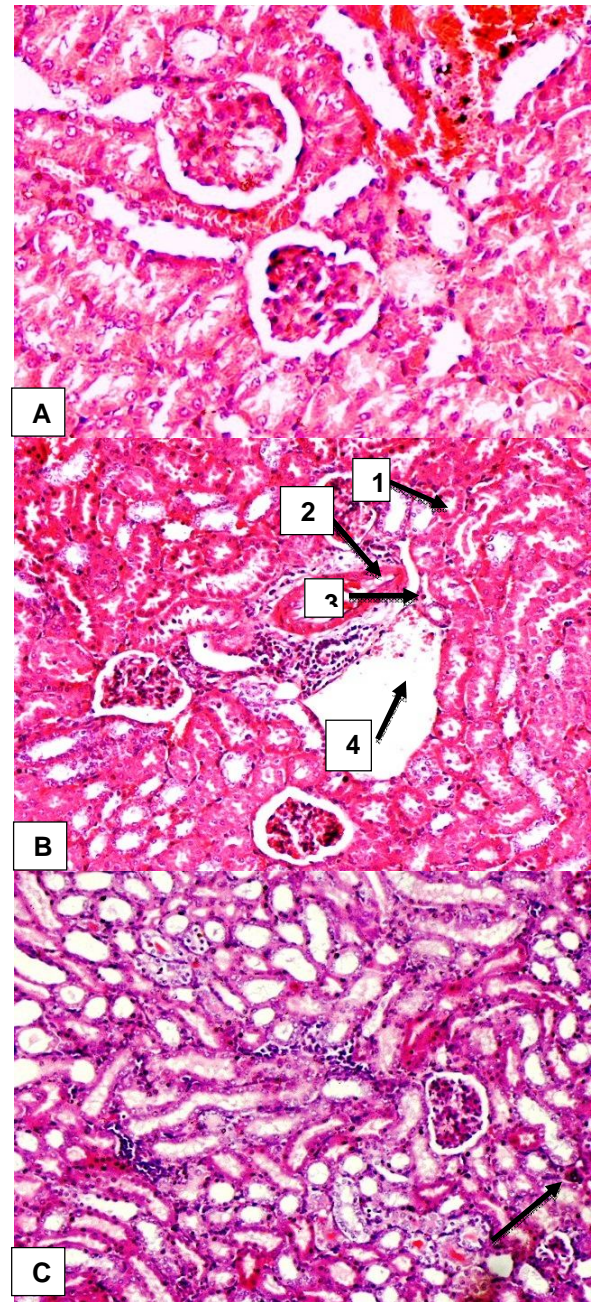


Fig. 1. Histological structure of mouse kidney after oral administration of Manuka honey for different periods of time, A, Normal kidney architecture; B, Glomeruli with mild mesangial proliferation (1), focal degeneration of tubular epithelial cells (2), vascular congestion (3) and chronic interstitial inflammatory infiltrate of moderate degree (4) as shown by the arrows; C, Mild interstitial inflammation in kidney as shown by the arrow. Stain: H & E; Magnification, A, x40; B, C, 20x.

It was of mild type in 5 (62%), 2 (25%), 8 (100%), and in 4 (50%) animals of 5, 10, 15 and 25 mL/kg (Fig. 2C), respectively. Moderate degree of interstitial inflammation was observed in 4 (50%) and in 1 (12%) animal in group 25 and 35 mL/kg, respectively, while 7 (88%) animals in the latter group demonstrated severe interstitial inflammation. Six (75%) of animals in group 10 mL/kg demonstrated minimal interstitial infiltrate (p-value 0.000). Glomerulus mesangial proliferation (Fig. 1B, arrow 1) was observed focally in 5 animals of group 10 μ l/kg and in all (n=8) of animals of groups 20, 25 and 35 mL/kg respectively (Fig. 2D) (p-value 0.000). Glomeruli capillaries were unremarkable in nearly all animals except in 7 (88%) (Fig. 2E) animals of 35 μ l/kg group where thickened vascular walls (Fig. 1B, arrow 3) were appreciated (p-value 0.000).

No animal mortality was observed from any experimental group throughout the experiment. A honey dose of 35mL/kg body weight brought some significant histological changes yet no mortality was observed. More than half of mice from all groups presented with increase in weight. Two of eight mice each from group 25 mL/kg and control maintained their weight. This number was 3/8 for group 25 μ l/kg and 1/8 for group 20 and 25 μ l/kg, respectively. Again 2/8 mice were observed to have a decrease in weight each from the groups 25 and 35 μ l/kg and 1/8 from group 20 μ l/kg. A significant difference was observed between weight of mice having different honey dose (p-value ≤ 0.05) when ANOVA test was applied.

DISCUSSION

An important and conspicuous finding was that there was no animal (n=48) mortality observed with any of the Manuka concentration given. The animals survived till the end of the experiment. Ponte *et al.* (2007) in Brazil reported 70% mortality of rats at 35mL/kg honey dose. In our study urine colour was normal in all mice except two from the 35 ml/kg body weight group which passed honey coloured urine. One possibility for this urine colour might be that at 35ml/kg body weight honey dose kidney tubular degeneration was observed in all (100%) animals of that group and 12% animals

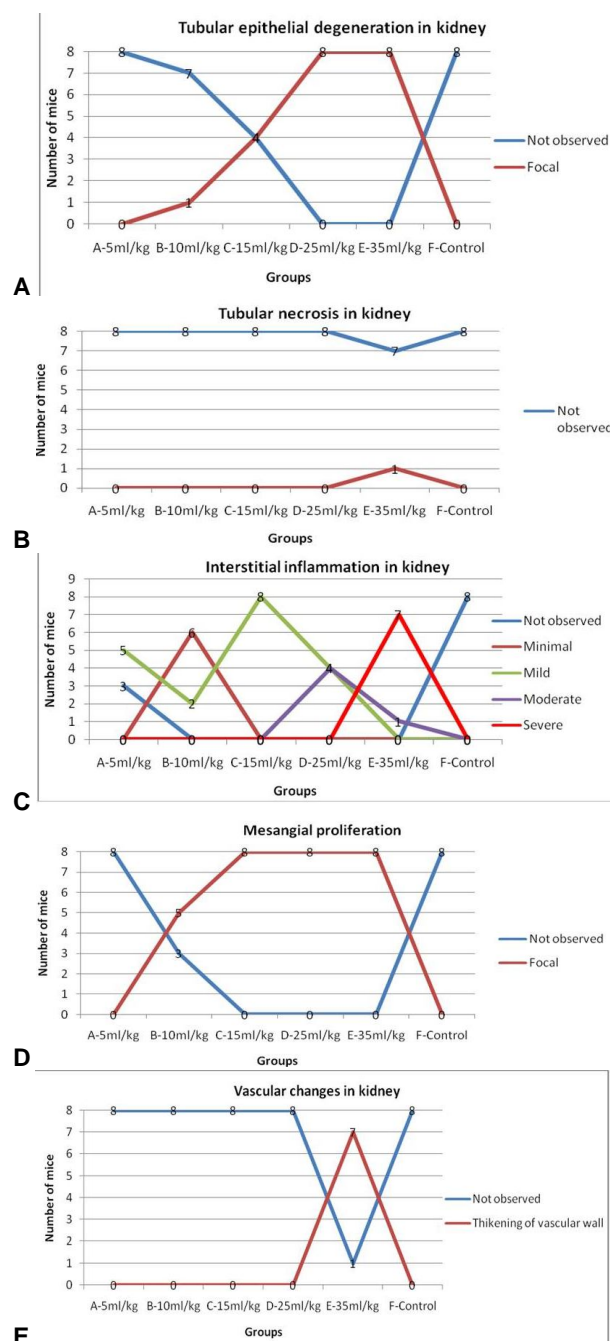


Fig. 2. Pathological changes viz., tubular epithelium degeneration (A), tubular necrosis (B), chronic interstitial information (C), mesangial proliferation (D), and vascular changes in kidney in response to Manuka honey at different doses (5-35 ml/kg body weight) in different groups (8 mice in each group) of experiment mice.

exhibited kidney tubular necrosis also. Another possibility for kidney damage might be presence of sugars in it that can elicit nephrotoxicity when given in high doses (Yudkin *et al.*, 1980; Triplitt, 2012).

Badawy *et al.* (2004) using different brands of honey administered subcutaneously to mice determined 1 ml as a safe dose, whereas higher dose produced mortality in mice. In contrast, we documented no mortality at any dose of Manuka honey given orally. The reason may be the different route of administration and/or different dose and dose schedule of honey given to the experimental animals.

In kidney, honey induced tubular epithelial degeneration in a dose dependent manner. Tubular necrosis was observed in only one mouse (12%) kidney and that too at the maximum dose *i.e.* 35mL/kg body weight. No tubular necrosis was observed in any other animal from any group. Chronic interstitial inflammation and mesangial proliferation were also observed in a dose related manner. Thickening of the glomerulus vessel wall was observed only at the maximum honey dose. It is clear that only higher doses of honey could elicit nephrotoxic changes.

Onyije *et al.* (2012) evaluated effects of different doses (0.1, .15 and .02 mL/kg body weight) of unprocessed honey on rat kidney and reported elevation of urea and creatinine at higher doses. The maximum dose in this study is far less than the minimal honey dose we used in our study. This study, however, supports our results that higher doses can be nephrotoxic.

Honey has been observed to be protective in cadmium induced nephrotoxicity at 0.05ml (50 μ L) daily dose (Wafaa and Hemmat, 2007), whereas in our study the least dose was 5mL/kg body weight (150 μ L). This least honey dose given in our study induced minimal/no changes in the kidney tissues. Halawa *et al.* (2009) also documented 1.5 mL/kg body weight protective effects of honey against lead induced oxidative stress in rats.

Although it has been proven that honey is protective against chemical induced toxicity in kidney at 'lower doses' (Abdel-Moneim and Ghafeer, 2007), the present study evaluated the dose tolerance of honey so that its uses as antimicrobial agent can be exploited in animal studies where high

doses of honey might turn lifesaving. Hence we also emphasize that Manuka honey can be further explored for its hidden potential even if it used in high doses.

ACKNOWLEDGEMENTS

We are grateful to Sameer and Usman Arshad both Laboratory Technologists in University of Health Sciences, Lahore, and Atika Masood, Assistant Professor, Akhtar Saeed Medical College, Lahore for their technical help.

REFERENCES

- ABDEL-MONEIM, W.M. AND GHAFEER, H.H., 2007. The potential protective effect of natural honey against cadmium-induced hypotoxicity and nephrotoxicity. *Mansoura J. Forensic Med. Clin. Toxicol.*, **12**: 75-78.
- AVMA, 2001. 2000 Report of the AVMA Panel on Euthanasia. *J. Am. Vet. Med. Assoc.*, **218**: 669-696.
- BADAWY, O.F., SHAFII, S.S., THARWAT, E.E. AND KAMAL, A.M., 2004. Antibacterial activity of bee honey and its therapeutic usefulness against *Escherichia coli* O157:H7 and *Salmonella typhimurium* infection. *Rev. Sci. Tech.*, **23**: 1011-22.
- BANCROFT, J.D., 2008. *Theory and practice of histological techniques*. 6th ed. Churchill Livingstone Elsevier, Philadelphia, PA.
- HALAWA, H.M., EL-NEFI AWY, N.E., MAKHLOUF, N. A. AND MADY, A.A., 2009. Evaluation of honey protective effect on lead induced oxidative stress in rats. *J. Arab Soc. med. Res.*, **4**: 197-209.
- HANNAN, A., BARKAAT, M., USMAN, M., GILANI, W. A., AND SAMI, W. 2009. *In vitro* antibacterial activity of honey against clinical isolates of multi-drug resistant typhoidal salmonellae. *Pakistan J. Zool.*, **41**: 1-6.
- IRISH, J., BLAIR, S. AND CARTER, D.A., 2011. The antibacterial activity of honey derived from Australian flora. *PLoS One*, **6**: e18229.
- JALALI, S.S., SAI FZADEH, F., TAJIK, S., FARSHID, H. AND ABBAS, A., 2007. Experimental evaluation of repair process of burn-wounds treated with natural honey. *J. Anim. Vet. Adv.*, **6**: 179-84.
- MAEDA, Y., LOUGHREY, A., EARLE, J. A., MILLAR, B. C., RAO, J. R., KEARNS, A., MCCONVILLE, O., GOLDSMITH, C. E., ROONEY, P. J., DOOLEY, J. S., LOWERY, C. J., SNELLING, W. J., MCMAHON, A., MCDOWELL, D. AND MOORE, J.E., 2008. Antibacterial activity of honey against community-associated methicillin-resistant *Staphylococcus aureus* (CA-MRSA). *Complem. Therap. Clin. Pract.*, **14**: 77-82.

- MEDHI, B., PRAKASH, A., AVTI, P.K., SAIKIA, U.N., PANDHI, P. AND KHANDUJA, K.L., 2008. Effect of Manuka honey and sulfasalazine in combination to promote antioxidant defense system in experimentally induced ulcerative colitis model in rats. *Indian J. exp. Biol.*, **46**: 583-90.
- MICHAŁOWICZ, J. AND DUDA, W., 2007. Phenols – sources and toxicity. *Polish J. environ Stud.*, **16**: 347-362.
- MULLAI, V. AND MENON, T., 2007. Bactericidal activity of different types of honey against clinical and environmental isolates of *Pseudomonas aeruginosa*. *J. Altern. Complem. Med.*, **13**: 439-441.
- MUNIRA, M.J., TAHIR, M., ASHFAQ, Q. AND SAMI, W., 2010. Effects of annona squamosa leave extract on gross congenital anomalies in diabetic albino rats. *Pak. Armed Forces med. J.*, **60**: 161-166.
- OLAITAN, P. B., ADELEKE, O. E. AND OLA, I.O., 2007. Honey: a reservoir for microorganisms and an inhibitory agent for microbes. *Afr. Hlth. Sci.*, **7**:159-165.
- ONYIJE, F. M., AVWIORO, O. G., ATONI, A. D., NDUKU, A. AND ZENEBO, V.C., 2012. Evaluation of the kidney following administration of unprocessed honey in wistar rats. *Asian J. med. Pharm. Res.*, **2**: 21-25.
- PONTE, F.L.R., SILVA, A.A.R. AND MAIA, M.B.S., 2007. Preclinical toxicity study of the phytomedicine- bee honey, propolis and Mikana glomerata extract in rodents. *Phcog. Mag.*, **3**: 203-212.
- SCHENCKE, C., SALVO, J., VEUTHEY, C., HIDALGO, A. AND SOL, M.D., 2011. Healing of burns type AB-B in guinea pig (*Cavia porcellus*) using ulmo honey associated with oral vitamin C. *Int. J. Morphol.*, **29**: 69-75.
- SERVAIS, H., ORTIZ, A., DEVUYST, O., DENAMUR, S., TULKENS, P. M. AND MINGEOT-LECLERCQ, M., 2008. Renal cell apoptosis induced by nephrotoxic drugs: cellular and molecular mechanisms and potential approaches to modulation. *Apoptosis*, **13**: 11-32.
- SIMON, A., TRAYNOR, K., SANTOS, K., BLASER, G., BODE, U. AND MOLAN, P., 2008. Medical honey for wound care—still the 'latest resort'? *Evid Based Complem. Alternat. Med.*, **6**: 165-173.
- SOUZA, V.B.D., OLIVEIRA, R.F.L.D., LUCENA, H.F.D., FERREIRA, A.A.A., GUERRA, G.C.B., FREITAS, M.D.L., QUEIROZ, K.C.D.S. AND JÚNIOR, R.F.D.A., 2009. Gentamicin induces renal morphopathology in Wistar rats. *Int. J. Morphol.*, **27**: 59-63.
- SUKUR, S.M., HALIM, A.S. AND SINGH, K.K., 2011. Evaluations of bacterial contaminated full thickness burn wound healing in Sprague Dawley rats treated with Tualang honey. *Indian J. Plast Surg.*, **44**: 112-117.
- TRIPLETT, C.L., 2012. Understanding the kidney's role in blood glucose regulation. *Am. J. Managed Care*, **18**: S11-S16.
- WAFAA, M. AND HEMMAT, H. G., 2007. The potential protective effect of natural honey against Cadmium-induced hepatotoxicity and nephrotoxicity. *Mansoura J. Forensic Med. Clin. Toxicol.*, **15**: 75-98.
- YUDKIN, J., KANG, S.S. AND BRUCKDORFER, K.R., 1980. Effects of high dietary sugar. *Br. med. J.*, **281**: 1396
- YUSOF, N., HAFIZA, A.H.A., ZOHDI, R.M. AND BAKAR Z.A., 2007. Development of honey hydrogel dressing for enhanced would healing. *Radiat. Phys. Chem.*, **76**: 1767-1770.

(Received 2 November 2013, revised 25 December 2014)